DENTAL IMPLANTS SUCCESSFULLY PLACED ON A FIBULA FLAP IN A PATIENT WITH OSTEORADIONECROSIS (ORN)

Martín-Granizo R., Millón A., Encinas A., Fernández E., Nuñez B., Falahat F., Berguer A.

Department of Oral & Maxillofacial Surgery.
Hospital Clínico San Carlos, Madrid, Spain

CASE REPORT

A 48 year-old male underwent **surgery** of a squamous cell carcinoma of the floor of the mouth, stage IV (T4N1M0). A bilateral functional neck dissection of the lymph nodes, a segmental resection of the inferior jaw from tooth 35 to 45 and an immediate reconstruction with a osteocutaneous free flap from the left **fibula** was performed. Three months later, treatment was completed with postoperative **radiotherapy** in a 50 Gy dose.

Twelve months later the patient started to have symptoms of infections over the fibular bone within the mandible, with fistula and necrotic fragments. An **osteoradionecrosis** (ORN) of the inferior jaw and the free flap was diagnosed.

1


2


3
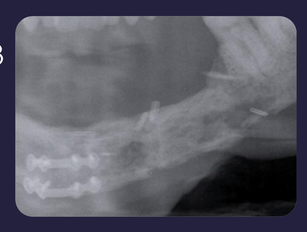

4
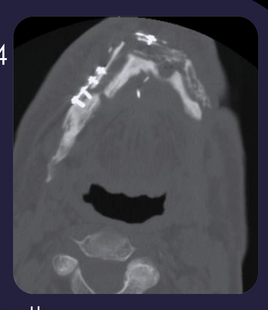

1: Intraoral view of the tumor of the floor of the mouth and mandibular symphysis.

2: OTG (2003) where areas of rarefaction are seen in the fibular flap.

3: Close view of OTG, area of ORN after removing the osteosynthesis.

4: CT of the mandible, where necrotic areas are observed.

EVOLUTION

After several surgeries for removal of the bony sequestra, patient underwent a first cicle of 30 sessions of **oxygen therapy** in an hyperbaric cabin (HBC), improving his symptoms. After another 16 months without clinical symptoms, he recurs and therefore a second cicle of 15 sessions of HBC and posterior sequestrectomy, what definitively stabilise the process. Ongoing follow-up with Xr and CT confirm the remission.

5
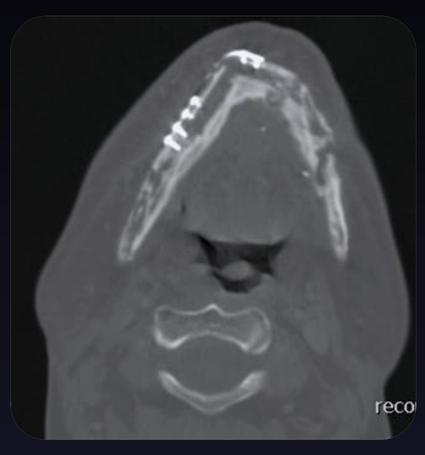

6


5: CT of the inferior jaw (2005) with an optimal evolution of the process. ORN, without progression. Still some necrotic areas are observed.

6: OTG (2006) improvement of the process with an increase of the density of the bone.

DENTAL REHABILITATION

7


8


9


10
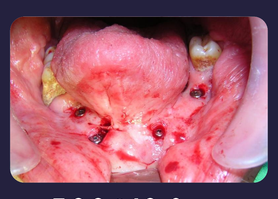

11
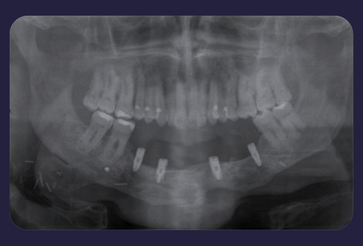

7,8,9 &10: Sequence of the insertion of dental implants on the fibular bone.

11: OTG 8 months after surgery. Osseointegration of dental implants is observed.

Fourteen months later, without evidence of ORN, a rehabilitation with **dental implants** is decided. Four screwed titanium dental implants (4,25 x 11,5 mm) with external hexagonal connection (RP) and surface RBM (*resorbable blasting media*) (Mozo Grau, SL, Spain) are inserted on the fibular flap.

Eight months later the implants were perfectly osseointegrated with good stability and therefore **healing screws** were placed. A removable dental prosthesis is made on a bar without mucosal contact. After 3 years the patient is free of disease with adequate health of his dental rehabilitation.

12


13


14
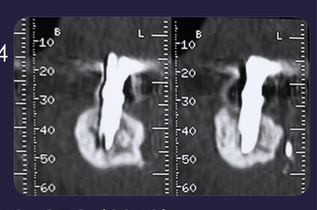

12: OTG (2012) Osseointegrated dental implants.

13 & 14: CT of the mandible (2012).

DISCUSSION

ORN is defined as the exposition of bone in a previously radiated tissue that does not heal after a 3 months period, without evidence of recurrence or residual tumor. In ORN a devitalization and devascularization of the bone is produced due to changes consequence of radiation. ORN is a complication of radiotherapy and can onset even several years after radiotherapy treatment, and can occur spontaneously. It usually is associated with a dental extraction or a previous bone trauma. The objective of the treatment is to improve vascularity and to remove death tissue.

HBC is used as an adjuvant therapy in patients with a stable ORN. Hyperoxygenation of radiated tissues stimulates angiogenesis and cellular proliferation and, thus, promotes osseogenesis. In cases of complicated or refractory to treatment ORN, a resection of tissues with healthy limits and an immediate reconstruction with vascularized microsurgical flaps.

To this date **we have not found similar cases reported in the indexed medical literature**.

RESULTS

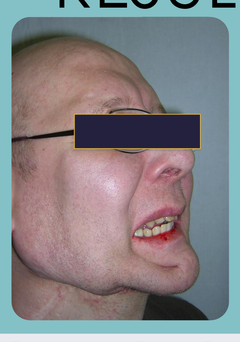

CONCLUSIONS

Vascularised fibular bone can support a dental rehabilitation with osseointegrated dental implants even if a previous ORN adequately treated, has occurred.

Hospital Clínico San Carlos

REFERENCES

•Marx RE. Johnson RR. Studies in the radiobiology of osteoradionecrosi and their clinical significance. *Oral Surg Oral Med Oral Pathol* 1987; 64: 379-390.
•Marx RE. A new concept in the treatment of osteoradionecrosis. *J Oral Maxillofac Surg* 1983 ; 41: 351-357.
•Schoen PJ, Raghoebar GM, Bouma J, Reintsema H, Vissink A, Sterk W, et al. Rehabilitation of oral function in head and neck cancer patients after radiotherapy with implant-retained dentures: effects of hyperbaric oxygen therapy. *Oral Oncol* 2007;43(4):379-88.
•Pitak-Arnnop P., Sander R., Dhanuthai K., Masaratana P., Bertolus C., Chaine A., Bertrand JC., Hemprich A. Management of osteoradionecrosis of the jaws: An Analysis of evidence. *EJSO* 2008; 34:1123-1134.
•Shaw R., Dhanda J. Hyperbaric oxygen in the management of late radiation injury to he head and neck. Part I: treatment. *Br J Oral Maxillofac Surg* 2011; 49: 2-8.